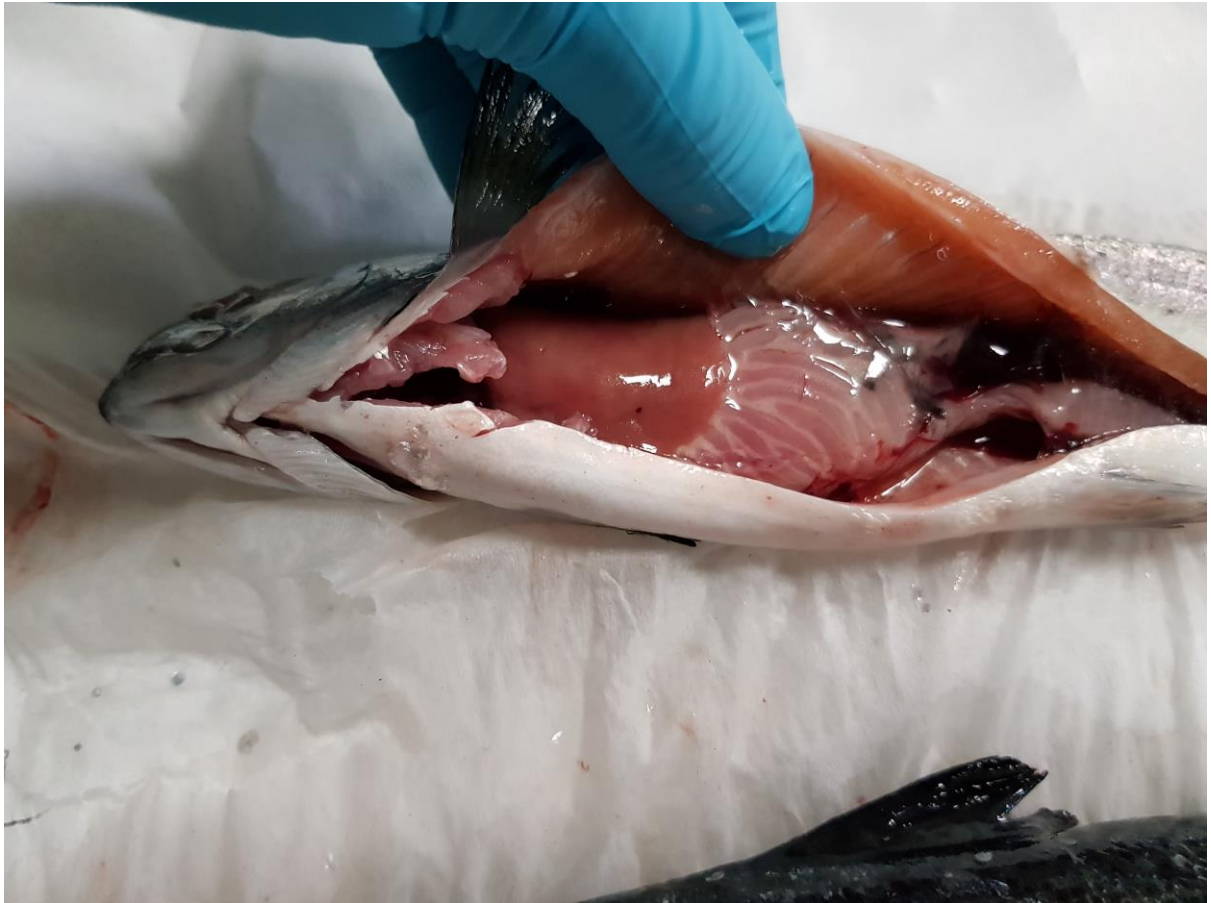



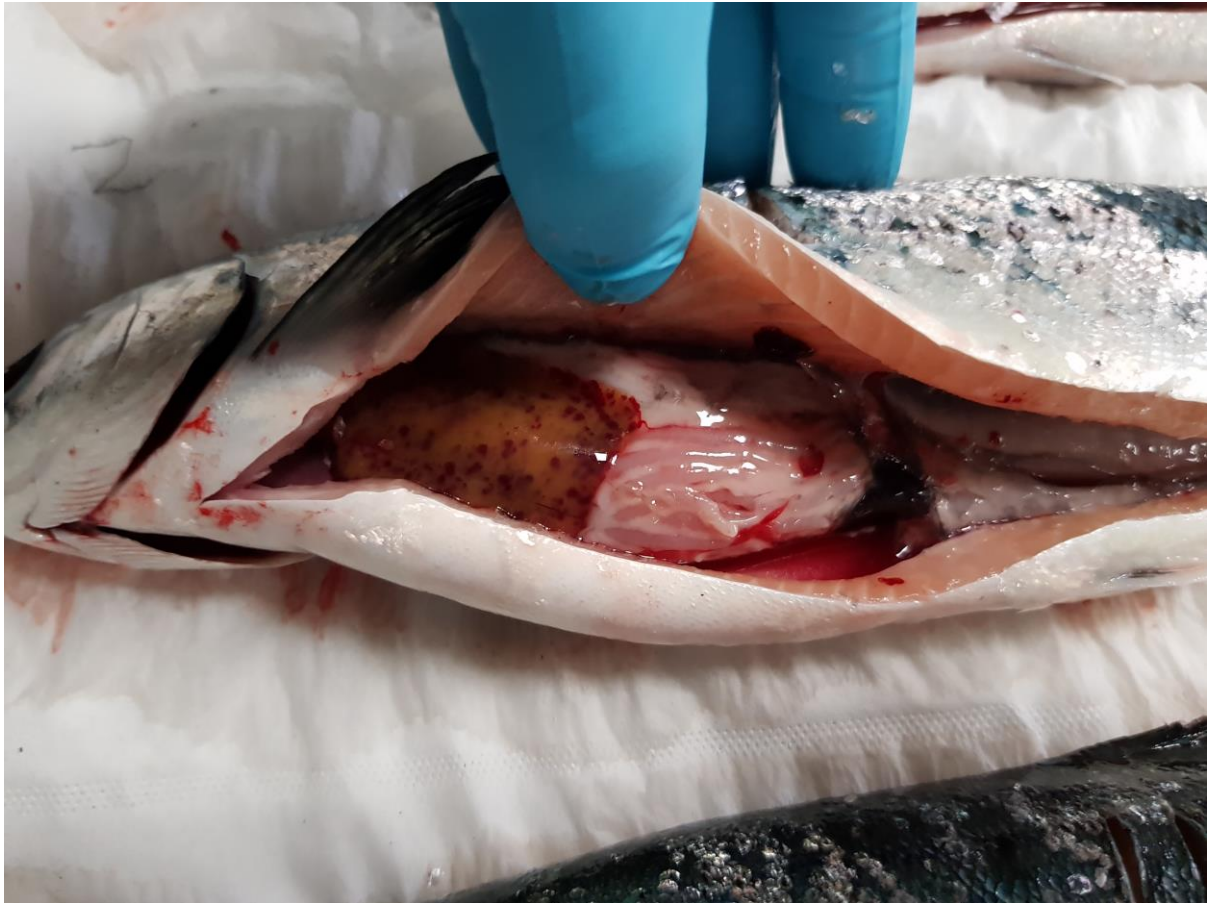
F1-3. F3 had anterior ventral lesion through which the heart was exposed.



F4-F5

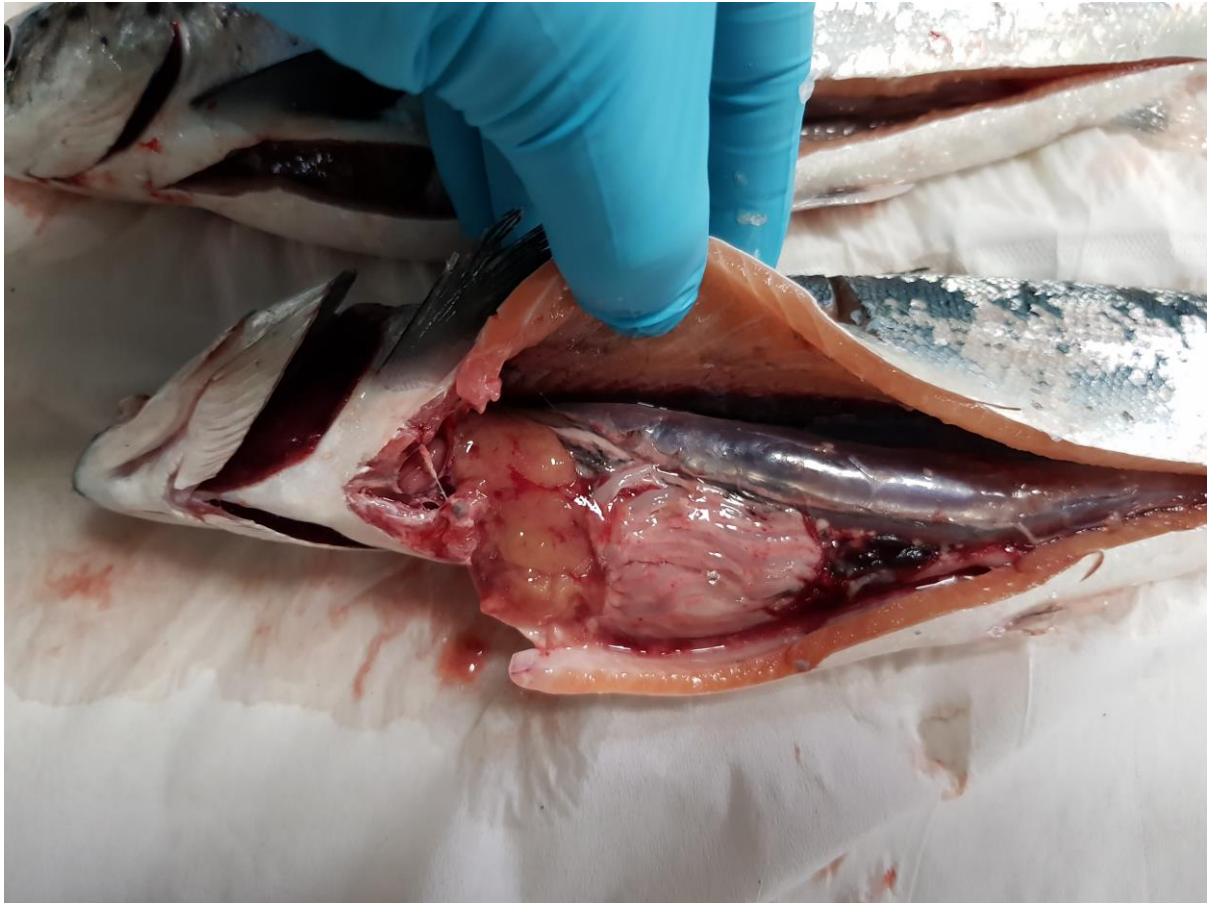


F1

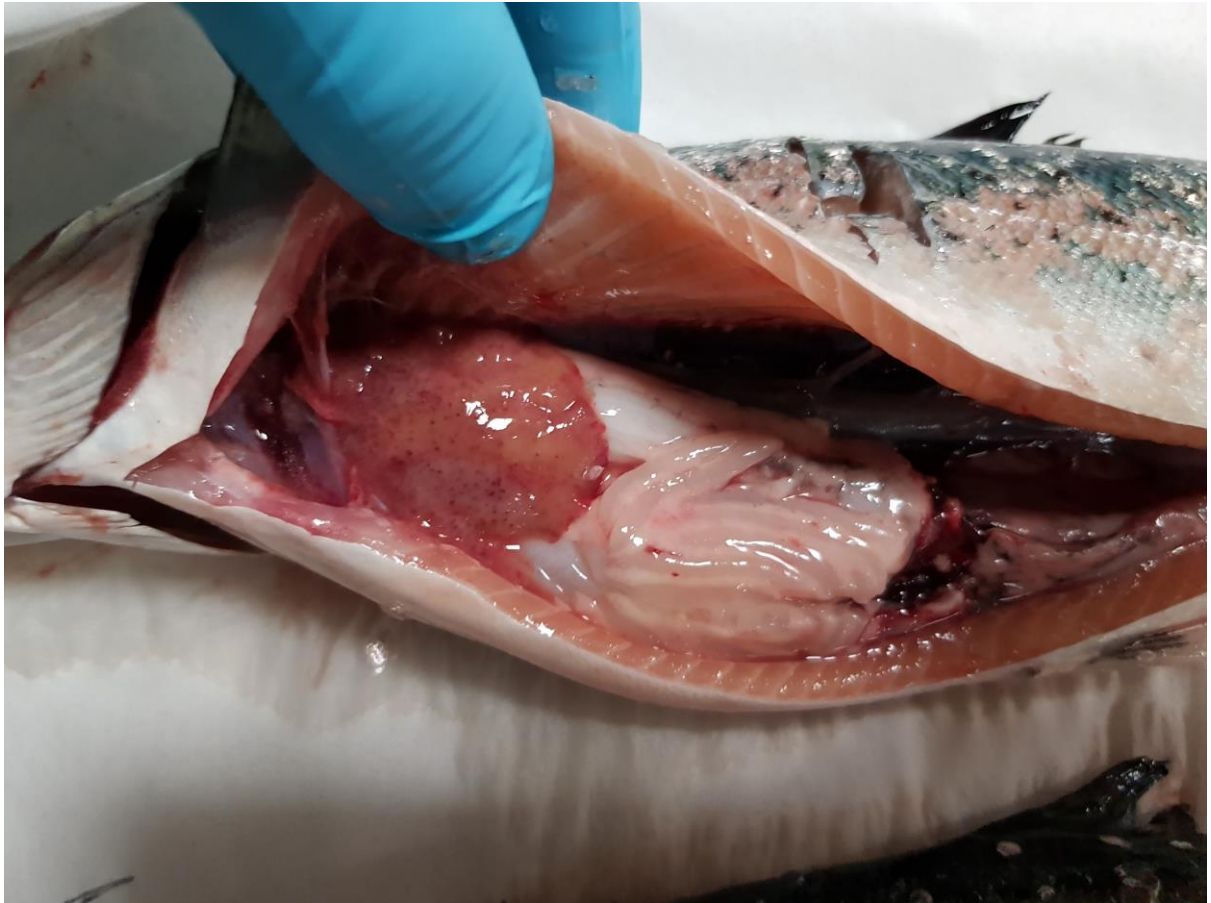

F2

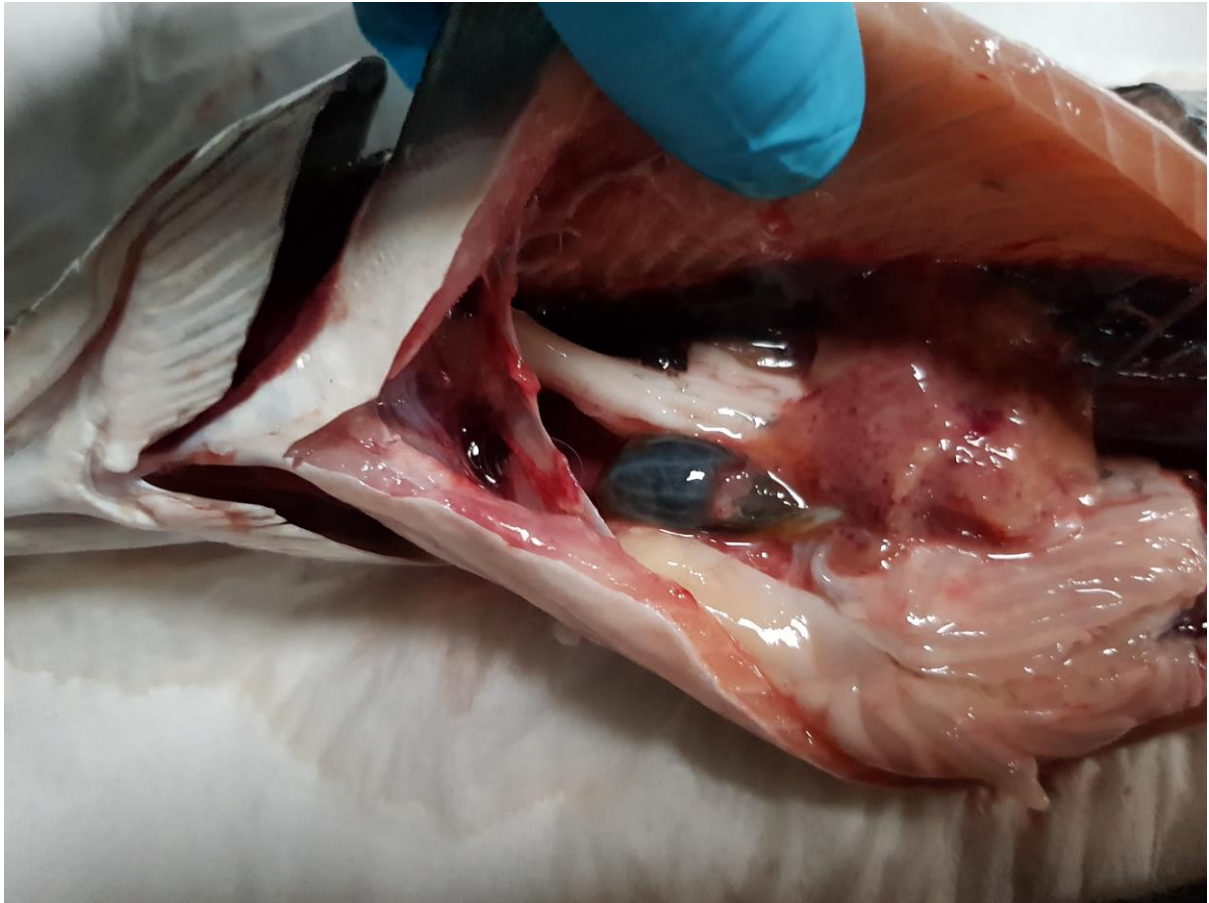




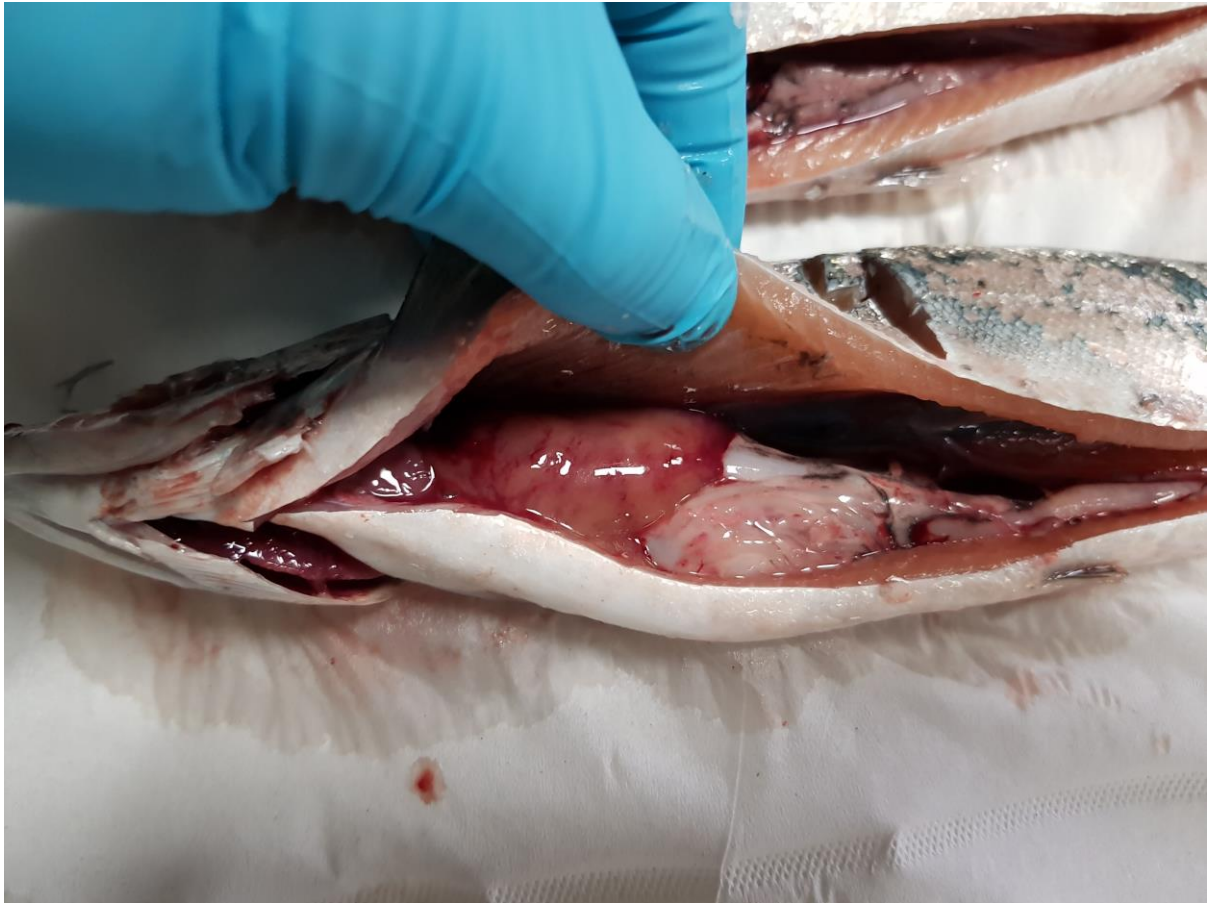F3



F4



F4 – Enlarged gall bladder observed underneath liver.



F5